


PATIENT

Grace Allen

PRESENTING CLINICAL SIGNS

History: Having panting episodes when rested inside air-conditioned house. No murmur.

SPECIES

Canine

ELECTROCARDIOGRAPHIC FINDINGS *Note: Single lead ECGs are evaluated as a rhythm strip. Morphology/MEA cannot be definitively commented on.

***ECG submitted 8-30-21**

A single lead ECG is available; 25mm/s, 20mm/mV. The average heart rate is 100bpm with a largely regular rhythm. The rhythm is sinus in origin, with a p for every QRS complex and vice versa. The P and QRS morphologies are positive. No ectopic beats, pauses or other dysrhythmias observed.

BREED

Boxer

ECG diagnosis: Normal sinus rhythm.

SEX

Female Spayed

ECHOCARDIOGRAM FINDINGS

2D, m-mode, color flow and doppler imaging is available. Normal mitral valve leaflets with no prolapse into the left atrial lumen. Trace mitral regurgitation with a normal left atrial dimension. Normal MR velocity. Normal LV diameter with adequate myocardial function. The tricuspid valve appears normal with no tricuspid regurgitation. Normal right atrial and ventricular diameter and morphology indicating no overt evidence of pulmonary arterial hypertension. The pulmonic and aortic valves are normal in morphology and mobility. Normal pulmonic and aortic outflow velocities with laminar flow. No obvious aortic or pulmonic insufficiency. No pericardial or pleural effusion noted. No obvious cardiac masses.

AGE

11 years

WEIGHT

55lbs

INTERPRETED BY

 Maggie Machen Lamy,
 DVM DACVIM
 (Cardiology)

CARDIAC CHART
IMAGING PERFORMED BY

Kelly Reschny, RVT

CANINE CARDIAC PARAMETERS	MR VMAX (m/s)	TR VMAX (m/s)	LA/AO (Boon method)	LA/AO (Heart Base; Swe)	FS (%)	EF (%)	EPSS (cm)
NORMAL PARAMETER	4.5-5.5	<2.7	1.3	<1.6	28-40	40-100	<0.6
PATIENT	4.74	NA	1.1	1.1	30	60	0.33
CANINE CARDIAC PARAMETERS	HR (BPM)	AV VMAX (m/s)	PV MAX (m/s)	BODY WEIGHT (kg)	LA 2D short axis Base view (cm)	LVIDd Avg; 2D and m-mode short axis (cm)	LVIDs Avg; 2D and m-mode short axis (cm)
NORMAL PARAMETER	50-100	0.7-1.7	0.7-1.6	BELOW	BELOW	BELOW	BELOW
PATIENT	NM	1.7	1.1	24.9	2.4	4.4	3.1
*Normal chamber parameters expressed as a mean value (SD)				3	1.27 (5.3)	2.46 (2.46)	1.36 (5.5)
BODY WEIGHT DEPENDENT PARAMETERS				5	1.40 (4.5)	2.74 (5.2)	1.60 (4.7)
*Note: All measurements based upon multi-modal images and methods. An average value is reported.				10	1.50 (3.8)	3.27 (3.5)	2.06 (3.1)
				15	1.83 (2.0)	3.71 (2.4)	2.43 (2.1)
				20	2.02 (1.9)	4.14 (2.2)	2.80 (2.0)
				25	2.18 (2.4)	4.48 (2.9)	3.10 (2.5)
				30	2.33 (3.3)	4.83 (3.9)	3.39 (3.4)
				35	2.48 (4.3)	5.17 (5.0)	3.69 (4.5)
				40	2.62 (5.2)	5.48 (6.1)	3.96 (5.4)
				50	2.88 (7.1)	6.07 (8.3)	4.46 (7.4)

 Adapted from June Boon, Veterinary Echocardiography, 1998
 Rishniw M and Hollis NE, J Vet Intern Med 2000; 14:429-435
 Hansson et al, Vet Rad and Ultrasound 2002
 Bonagura et al. Echocardiography: principles of interpretation, Vet Clin North Am 15:1177, 1995

HOSPITAL NAME

 The Maples Animal
 Hospital

REFERRING VET

Dr. Kazienko

INVOICE

20661

DATE

8/20/21



PATIENT

Grace Allen

SPECIES

Canine

BREED

Boxer

SEX

Female Spayed

AGE

11 years

WEIGHT

55lbs

INTERPRETED BY

Maggie Machen Lamy,
DVM DACVIM
(Cardiology)

IMAGING PERFORMED BY

Kelly Reschny, RVT

HOSPITAL NAME

The Maples Animal
Hospital

REFERRING VET

Dr. Kazienko

INVOICE

20661

DATE

8/20/21

INTERPRETATION OF THE FINDINGS & FURTHER RECOMMENDATIONS

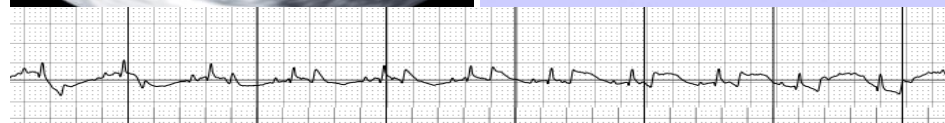
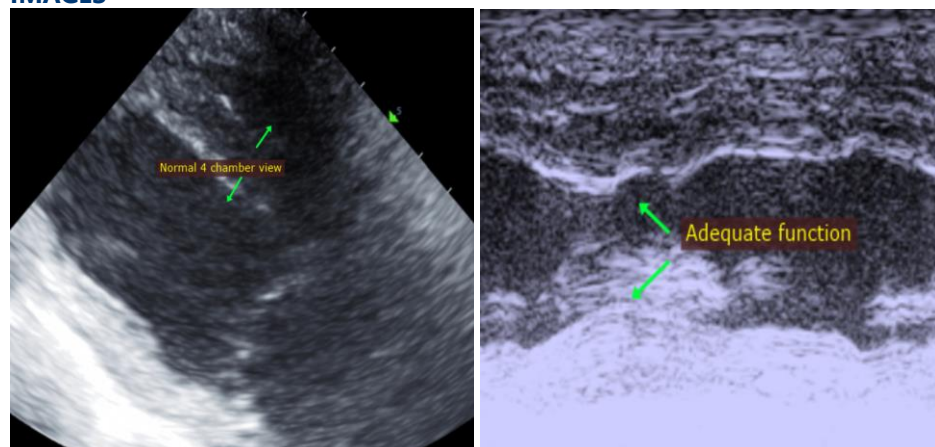
Overtly normal cardiac dimensions and function, with no obvious dysfunction or dilation of the left heart. No significant valvular leaks are visualized, and no evidence of pulmonary hypertension.

Giving these findings, inappropriate panting is unlikely to be cardiac related. The submitted ECG is normal, with no evidence of dysrhythmias. If arrhythmias are suspected regardless of this tracing, a longer recording or potentially a holter monitor may be necessary should the episodes persist undiagnosed.

Monitor for development of a heart murmur, cough, labored breathing, exercise intolerance or collapse episodes.

A recheck echocardiogram is recommended should a significant murmur develop, or signs of cardiac compromise be noted in the future.

IMAGES



The information and recommendations provided are based on the images presented by the referring veterinarian. No evaluation can be communicated regarding pathology that was not visible in the image/video clips provided.

Thank you for this referral. This report was generated using transcription software, and minor dictation errors may be present. If the clinical or image interpretation does not parallel your findings or if I can be of any further assistance, please contact me.

Maggie Machen Lamy, DVM
Diplomate of the American College of Veterinary Internal Medicine (Cardiology)
info@sonopath.com